

Digestive Pathology

Disorders Of The Mouth

Oral Cavity – General

The oral cavity is easily examined during clinical and postmortem examinations. A thorough examination of all structures will reveal not only local lesions but often those which may be due to systemic disease.

- ✓ *Icterus* – The oral mucous membranes and gingiva appear yellow.
- ✓ *Anemia* – The mucous membranes appear pale.
- ✓ *Cyanosis* - A gray tinge to the mucosa is an indicator of inadequate oxygenation and may be a reflection of cardiovascular disease.
- ✓ *Uremia* - Ulcers on the epithelium adjacent to the salivary duct openings are an indication of uremia.

✓

Congenital Anomalies

Cleft palate, or *palatoschisis*, is one of the most common anomalies in calves. It is a congenital defect that occurs as a result of failure of growth and fusion of the palatine shelves from the maxillary processes. Consequently, a “cleft” or central defect allows oral and nasal cavities to communicate in the hard palate area, which makes for problems, like can’t suckle, and/or stuff headed for the stomach goes to lungs instead.

Anomalies in the growth of the jaws are quite common.

Agnathia is the absence of the mandible altogether. Not compatible with life.

***Brachygnathia* (shortened jaw) and *prognathia* (lengthened jaw) are named according to where they occur.**

Inflammation of the oral cavity

The general word for inflammation of the oral cavity is stomatitis.Inflammatory processes may be localized to specific tissue and given specific names. *See the list below.*

lips – cheilitis

pharynx – pharyngitis

tongue – glossitis

gums – gingivitis

tonsils – tonsillitis

. They exist in harmony with the host largely due to routine host defenses, including

- □squamous composition of the epithelium (impermeable),
- □lysozyme from saliva, and
- □immunoglobulins in oral secretions.

If this balance becomes altered, the endogenous flora may take advantage of the situation and proliferate to cause disease. *Thrush*, or *oral candidiasis*, occurs most commonly in foals, pigs, birds and dogs. It is a common indicator of severe immunosuppression and may be associated with severe stress.

Trauma

Trauma is often a precipitating factor in stomatitis. In dogs and cats, sharp bones, splinters, thorns, and maloccluded teeth can all cause traumatic injury.

Viral stomatitis

➤ *Viruses* can cause stomatitis in three ways -

1. They **may invade and replicate in the oral epithelium, killing it and making ulcers**, with necrosis. Herpesviruses operate this way.
2. Or, viruses may **infect the underlying vasculature** and cause ischemic necrosis of the epithelium overhead. This ischemic mucosa then sloughs, leaving an ulcer. Examples of viruses that work via this category would be bluetongue and malignant catarrhal fever.
3. Viruses may **infect epithelial cells**, and cause a vesicle (foot-and-mouth disease) or just make the epithelium proliferate and maybe even ulcerate (orf).

Deep Stomatitis

When the inflammation extends well below the surface epithelium, the condition is considered to be a "deep stomatitis." Some of these entities include:

Wooden tongue - Caused by *Actinobacillus lignieresii*, it is a granulomatous reaction in the deep tissues of the tongue, in cattle. This organism is part of the normal oral flora; when the defenses are disrupted, such as might happen with a penetrating wound, the organism is allowed access to deeper structures, and incites this granulomatous reaction.

The tissue becomes very firm, so much so that the common name for this disease is "wooden tongue." Sometimes yellow granules are seen grossly in this inflammation - these are called "sulfur granules", are very characteristic, and consist of individual inflammatory

foci with abundant bacteria.

With this disease, the animal cannot move the tongue very well, and so it can't eat properly. It will get very thin.

Another deep stomatitis seen in the cow is "***lumpy jaw.***" It often causes a grossly disfigured mandible, hence the name. The cause is *Actinomyces bovis*. This organism also is common in the oral cavity but with a penetrating wound will move even farther than *A. lignieresii* cares to venture, and will destroy bone. The main lesion is a pyogranulomatous osteomyelitis, with disfigurement of the mandible.

Fusobacterium necrophorum is an anaerobe that is commonly found in the oral cavity and will get in to cause trouble whenever possible. The hallmark of inflammation with this organism is necrosis. It is a supreme secondary invader, often coming in to complicate and prolong a simple ulceration due to trauma or viral infection that, without the aid of *F. necrophorum*, would heal simply.

Toxic stomatitis

Many plants can cause a toxic stomatitis due to the corrosive properties in their leaves or stems. ***Diffenbachia, Croton and Caladium spp. (elephant ear)*** are all plants that can cause a toxic glossitis and stomatitis.

Uremia is an important endogenous toxin that leads to oral ulceration. The oral ulcers due to uremia are fairly typical and occur opposite salivary gland openings on tongue and oral mucosa. Uremic "toxins" excreted in saliva react with bicarbs (also in saliva), and bingo, mineral and ulcers form.

Immune-mediated stomatitis

Plasma cell stomatitis is a specific disease of cats, characterized by infiltrates of, you guessed it, plasma cells. Typically, the lesions begin as bilateral, raised, often superficially ulcerated, proliferative masses at the caudal part of the hard palate. The cause is presumed to be immune-mediated because treatment with steroids helps to resolve lesions.

oral neoplasia

Not so bad but look pretty awful:

Oral papillomatosis occurs in dogs and is due to a virus. Lesions usually regress after a while, but while they are around might cause serious problems with eating or infections.

And the bad ones:

Squamous cell carcinoma is a frequent malignant oral tumor of cats and dogs. They tend

to **be invasive** and **metastasize readily to regional lymph nodes and lungs**. This is the most common oral tumor in the cat.

Malignant melanoma is the most common malignant neoplasm of the oral cavity in dogs. They tend to **be highly invasive** and **metastasize early**. It is rare in other species. VERY BAD.

Oral fibrosarcomas occur mainly on the gums of the upper molars and adjacent palate. They invade bone and tend to recur after surgical removal. Metastasis to lymph nodes and lungs is common.

Osteosarcomas can occur in the bones of the upper and lower jaws.

Diseases Of Teeth

Enamel Hypoplasia

The ameloblasts produce all the enamel of a tooth. Several conditions can damage ameloblasts and the result is decreased enamel.

Canine distemper virus can affect **ameloblasts** and **enamel hypoplasia** can be seen in dogs recovering from canine distemper infections. The teeth of these dogs appear pitted and roughened due to lack of the smooth shiny enamel surface.

Other conditions that affect ameloblast function to cause enamel hypoplasia are high fevers, bovine viral diarrhea virus, excess fluoride, calcium deficiency, and tetracyclines given during gestation.

Other Developmental Abnormalities

The following is a list of names used to describe these other tooth abnormalities Anodontia
-----lack of tooth development

Oligodontia -----development of less than the normal number of teeth

Pseudoligodontia-----failure of teeth to erupt

Polyodontia-----presence of more than the normal number of teeth

Pseudopolyodontia-----retention of deciduous teeth

Heterotopic polyodontia-----presence of teeth in locations other than dental arcade.

Oligodontia and polyodontia are thought to be inherited traits in brachycephalic dogs. In these breeds, it is not uncommon to find missing molar teeth (oligodontia) while polyodontia generally involves the incisor teeth. In toy breeds, oligodontia affects the incisors. Oligodontia has also been seen in horses and cats.

dental calculus and plaque

Dental calculus and plaque are two conditions that can lead to tooth loss in domestic

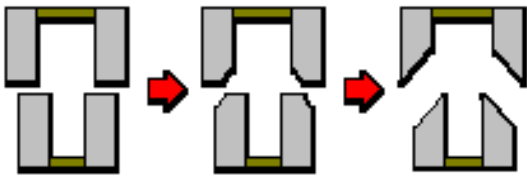
animals. This is a problem of dogs and cats.

➤ *Dental plaque* is a deposit of bacteria adherent to the tooth surface that resists removal by salivary flow (pellicle). The bacteria that form plaque are usually Gram positive (streptococci and *Actinomyces* spp.) and secrete polymers that help them adhere to each other and the tooth. Plaque is metabolically active and produces enzymes and other mediators of inflammation.

Malocclusion

In rats and rabbits, malocclusion can lead to bizarre over growth of the incisors resulting in difficulty in mastication. Abnormal wear of teeth can result in irregularities of the tooth surface.

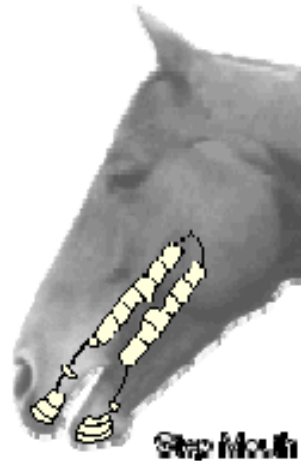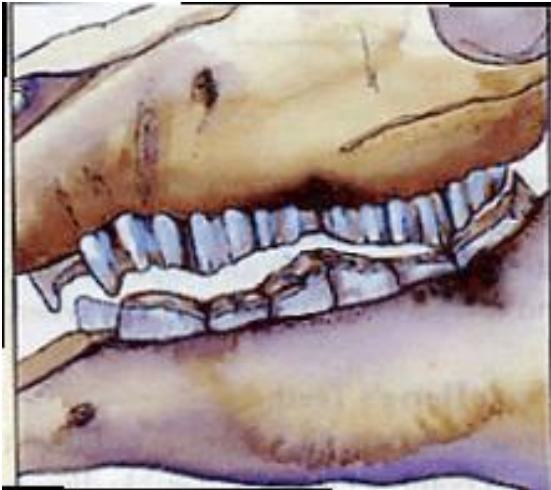Another example of malocclusion is *points* in horses. Inadequate lateral movements of the jaw can result in excessive growth of the buccal and/or lingual surface of the teeth. This excessive growth takes the form of sharp edges or points on the inadequately worn surfaces. The points can cause tears on the tongue and inner surface of the mouth.



Wave mouth is due to teeth wearing at different rates from improper mastication with step mouth inadequate antagonism of the opposing teeth, or from abnormalities in the hardness of the teeth. The name is descriptive as the dental arcade resembles waves in the ocean, sort of...

Another severe form of attrition is **step mouth**. This is seen when the opposing tooth is absent so no opposing wear occurs. As a result, the tooth continues to erupt and has a much higher occlusal surface than adjacent teeth.

Broken mouth is common in old sheep. The teeth are so worn and/or misshapen/missing, that even though provided with plenty of pasture or feed, the animal just can't chew enough to allow for proper nutrition.



PIGMENTATION

A congenital disease called *congenital porphyria* can also cause abnormal pink discoloration of teeth as well as bones. Affected animals have defective hemoglobin that is degraded abnormally and the products of this degradation are deposited as red to pink pigment in tissue. It is especially apparent in teeth.

The Normal Salivary Gland

There are three main salivary glands in domestic animals; the submandibular (also known as the mandibular), the parotid, and the sublingual. They make amylase, which gets the whole starch digestion thing started, and mucin, which helps to move the bolus along.

Vocabulary - Salivary Gland

Ptyalism means excess production of saliva. It is seen in specific conditions, such as heavy metal poisoning but is probably most commonly seen in association with stomatitis of any cause.

Aptyalism means reduced salivary secretion. It is less common than ptyalism but may be seen with fever, severe dehydration, or salivary gland disease.

Sialoadenitis is the term used to describe salivary gland inflammation. There are only a

handful of conditions in animals that cause primary sialoadenitis.

Sialoadenitis is the term used to describe salivary gland inflammation. There are only a handful of conditions in animals that cause primary sialoadenitis.

Sialoliths are **STONES** that form in the salivary ducts. They are composed primarily of calcium carbonate, and are the result of chronic inflammation or foreign bodies. Sialoliths may cause obstruction of the ducts if large enough and this obstruction could lead to cystic dilation of the duct known as *ranula*.

Tumors Of Salivary Gland: Most Are Malignant And Spread Quickly

DISORDERS OF THE ESOPHAGUS NORMAL VERSUS ABNORMAL

There are some species variations in esophageal morphology that can be confusing. For instance, horses sometimes have striking muscular hypertrophy in the caudal portion of the esophagus and yet there is no clinical abnormality. To the uninitiated, this would appear to be problematic and a cause for stricture, but in fact, has no clinical significance.

Esophagitis:-erosive and ulcerative esophagitis accompanies with stomatitis and they follow ingestion of corrosive chemicals.

Stenosis of esophagus:-development defect or be acquired following scarring of wall or tumor growth.

DYSPHAGIA(diffecult in swallowing).

Dysphagia is the term for disorders of swallowing. Since swallowing is a highly complex activity, it is divided into three phases. A disorder in any of these 3 phases may cause difficulty in swallowing, or dysphagia.

□□**Oral phase dysphagia** is caused by lesions in the oral cavity or tongue. Any lesion or abnormality which interferes with the delivery of the bolus to the pharynx will cause oral phase dysphagia.

Stomatitis, glossitis, gingivitis, and cleft palate are all examples. A cow with foot-and-mouth disease that is drooling liters of saliva has oral dysphagia.

□□**Pharyngeal phase dysphagia** can be caused by pain in the pharyngeal region (from pharyngitis, tonsillitis, abscesses) or proliferative masses that intrude on the pharyngeal space causing inability to swallow. Neuromuscular diseases affecting the tongue and pharynx can cause dysphagia.

□□**The third phase of swallowing involves the esophagus.** The bolus must enter the esophagus - if the esophagus fails to dilate or the upper esophageal sphincter does not accept the bolus, it is *esophageal dysphagia*. Most commonly, this is a result of a neurologic defect and the disorder is termed cricoesophageal incoordination or *achalasi*

Megaesophagus

Dilation of esophages

Megaesophagus occurs predominantly in dogs, horse, cat It can be congenital (born that way) or it can occur as a result of a neurologic problem later in life.

Choke:-follow stenosis or ingestion of insufficient chewed potatoes or apples mass,of grain or bone,most frequently occur thoracic inlet heart base and diaphragmatic hiatus.

In cattle, this can be an emergency, because if cattle can't eructate and release gas from their rumen, they bloat and bloat is life threatening. Bloat will be covered in more detail in the section on forestomachs. However, the characteristic postmortem lesion of bloat is present in the esophagus so we'll cover that here. The pathognomonic lesion of bloat is a "*bloat line*" that occurs at the thoracic inlet in cattle that bloat. It's not really a line, but rather a BORDER. The increased thoracic pressure from the rumenal distention results in esophageal ischemia (in the thoracic part),.

the neck region is normal or congested. So, there is a line at the thoracic inlet, separating congested from ischemic tissues. Look at the esophageal mucosa from this case of bloat thoracic portion is white (because of high pressure pushing blood out) and cervical portion is red (because of congestion, blood here can't get back to the heart).

A complication of choke occurs when the stuck object presses against the esophagus hard enough to cause **segmental necrosis**. This leads to ulceration. And, if the necrosis is severe enough, scarring occurs and there is a stricture left. These *strictures* can hinder an animal's production for the rest of its life.

Another sequela to having a foreign body in the esophagus is that a **diverticulum** will form, that is, the foreign body will push hard enough on the mucosa that it herniates through the muscularis and develop a fibrous wall surrounding it. This is better than the alternative which is that the foreign body pushes through the esophagus so that the esophagus perforates completely (esophageal fistula) and the foreign body ends up in the adventitia and can incite a tremendous cellulitis and, if within the thorax, **severe thoracic inflammation**

ULCERATION

Ulceration of the esophagus causes problems for all of the same reasons listed above. That is, ulcers in the cranial portion of the esophagus can be very painful and result in dysphagia. Healing of ulcers may cause strictures or, ulcers may be so severe that they result in

perforation.

Esophageal ulceration due to gastric acid reflux is seen most commonly in the caudal portion of the esophagus in monogastric animals. The stomach fluid is very acid and the gastric mucosa protects itself with buffered mucus. However, the esophageal squamous epithelium has no innate buffering capacity. So, when stomach fluid gets into the esophagus through gastric reflux, it can be very bad for the esophagus. Burn burn burn. Anyone who has ever had heart burn, that's what it is, gastric acid burning the esophageal mucosa. If the reflux is severe or prolonged, ulcerative esophagitis results.

Some toxins are known for their ability to cause esophageal ulceration. Blister beetles (*Epicauta lemniscata*) contain a toxin, cantharidin (also known as Spanish fly), which causes epithelial cell necrosis in the tissues it contacts. These blister beetles may be baled along with alfalfa hay. When horses (and other monogastric animals) ingest them, necrosis and ulceration can occur in esophagus, stomach, urinary bladder, and urethra.

Some viral agents are noted for their ability to cause esophageal ulceration. Some viruses of cattle that will cause ulceration include malignant catarrhal fever, rinderpest, infectious bovine rhinotracheitis, and bovine papular stomatitis.

NEOPLASIA

The esophagus is a not uncommon place for *papillomas* to develop, especially in calves. A virus is responsible. They usually cause no clinical signs and are merely incidental findings at necropsy. If extensive, or critically located, they may interfere with swallowing or eructation. Here is a papilloma at the rumino-reticulo-omasal orifice, right at the end of the esophagus. Although this small growth is benign, it interfered with food passage and the calf died

Spirocerca lupi is a nematode parasite carried by dung beetles. If dogs ingest the dung beetle, with the parasite inside, the parasite encysts around the esophagus. There is leads to TUMORS - fibrosarcoma or osteosarcoma. It can also cause a space-occupying lesion that predisposes to hypertrophic pulmonary osteopathy (HPO)

Disorders Of The Forestomachs

Rumenitis due to lactic acidosis

Ingestion of diets high in grain (carbohydrates) can result in a life-threatening condition called lactic acidosis. Increased fermentation of carbohydrates causes a shift in the rumen microflora to favor *Streptococcus bovis* that tolerates the lower pH (<5) created by the accumulation of volatile fatty acids. As the pH lowers, lactobacilli begin to predominate and large amounts of lactate accumulate in the rumen. Some lactate diffuses into the blood stream creating systemic acidosis. At the same time the osmotic pressure of the lactate in the rumen draws body fluids into the rumen resulting in hemoconcentration and dehydration. Diarrhea often develops and the animal dies from **hypovolemic shock**. If the animal survives the acute episode, the rumen mucosa may be damaged resulting in ulcers and erosions. These erosions and ulcers may be secondarily infected with fungi resulting in mycotic rumenitis.

Ulcers often provide a breach for *Fusobacterium necrophorum* or *Corynebacterium spp.* to gain entry to the blood supply and cause hepatic abscesses and hepatic necrosis. These hepatic lesions are common in feedlot cattle fed high concentrate diets.

There is also a more chronic problem with ingestion of feed that is high in carbohydrates, or, when there is a sudden decrease in amount of forage. This causes the ruminal epithelium to proliferate, but not a good way. The slightly increased acid, from too many volatile fatty acids in the rumen, cause the epithelium to get thicker (metaplasia) and then it is less absorptive. So the volatile fatty acids get passed on through into the small and large intestine, and they carry water with them, resulting in a chronic diarrhea. Also, because the pH of the rumen is lowered, there are more bacteria there and some of them will also pass into the intestine and may create low grade enteritis, which causes diarrhea as well.

Many of the ruminal papillae have become darker and they are more firm than normal, this is ruminal parakeratosis that occurs in subacute ruminal acidosis. These animals will have diarrhea and be thin.

Rumen tympany

Rumen tympany or bloat is common in cattle and represents a life threatening emergency.

Primary bloat is also called frothy bloat. Plant materials high in soluble proteins such as legumes, especially alfalfa, are often the offending substances. The proteins are partially degraded by microbes and become denatured so that they stabilize the foam. These small gas bubbles do not coalesce into larger bubbles so that the accumulated gas cannot be eructated. In order for an animal to eructate, the receptors near the esophagus need to be exposed to AIR – a lot of small stable bubbles don't qualify as AIR.

Consumption of feed material that is high in legumes (like alfalfa) will cause FROTH to form in the rumen and all those little bubbles can't be eructated.

Secondary bloat results in accumulation of gas due to an inability to eructate the normal gas from the rumen. Causes include obstruction of the esophagus, vagal nerve paralysis, and adhesions.

Primary and secondary bloat result in increased pressure on the diaphragm to the point that the animal suffers from severe hypoxia. It is important to distinguish antemortem bloat from postmortem bloat because rumen fermentation will continue after death and tremendous amounts of gas will accumulate. See the "bloat line" in the esophagus. The gas distention prior to death should result in congestion of the head and neck so that a line of congestion separates the proximal and distal esophagus and sometimes the trachea. Bloat lines don't happen after death. The heart has to be beating in order to get congestion.

This appearance of the esophageal mucosa is diagnostic for bloat. The thoracic part of the esophagus is on the left, where structures have all been compressed because of the pressure and blood is not present in the capillaries due to all this pressure. On the right is the cervical part (more anterior) of the esophagus, where everything is congested because blood can't flow back into the thorax due to the high pressure.

Gastric inflammation

Any acute disruption in the stomach can cause acid to enter the mucosa and eat through, causing ULCERS.

Gastric Ulceration – glandular stomach

For ulceration to occur, there has to be an imbalance between the necrotizing effects of gastric acid and pepsin on one hand, and the ability of the mucosa to maintain its integrity on the other.

✓ Hypersecretion of hydrochloric acid may be due to increased parietal cell mass or increased release of HCl from parietal cells as a result of increased histamine levels. Increased histamine levels are seen in dogs with *mast cell tumors* – the neoplastic mast cells release histamine which then stimulates the parietal cells to secrete HCl.

✓ Administration of NSAIDS (NonSteroidal AntiInflammatory DrugS) can cause gastric ulcers. In the stomach, prostaglandin-mediated vasodilation, modulation of histamine-induced acid secretion, and stimulation of bicarbonate secretion by mucous cells is dependent on adequate prostaglandin levels. Without the PGs, the mucosa is open to attack by gastric acids with resulting necrosis and ulceration.

✓ *The role of glucocorticoid release* on ulcer formation is controversial. The administration of steroids may cause increased gastrin and acid secretion. *Steroids* decrease reparative gastric epithelial-cell turnover and, by stabilizing membranes, decrease the availability of arachidonic acid for prostaglandin synthesis. This results in compromise of the mucosal integrity and ulceration.

Ulcer progression

Once the superficial portion of the mucosa is destroyed, natural local buffering by surface cells is lost, and the proliferative compartment of the gland, which is near the surface, is obliterated, preventing a local epithelial reparative process. Necrosis then extends rapidly to the muscularis mucosae causing necrosis.

If the necrosis continues, the ulcer may extend through the muscularis and serosa and results in *perforation* of the gastric wall.

Any chronic inflammation in the stomach will lead to **atrophy**. With atrophy there is a decrease in the parietal cell mass which means less HCl and therefore no protein digestion. Because protein can't be broken down once past the stomach, those big osmotic molecules just move right on through the tract, taking lots of water with them and being completely

unavailable for absorption. Therefore diarrhea.

Ostertagiasis in the abomasum of cattle is an example of a disease that causes gastric atrophy. And when the stomach mucosa is atrophied, there is poor digestion, proteins can't be broken down, they just move on through, carrying water with them, and that means DIARRHEA.

Gastric Neoplasia

What are the cell types in the stomach?

GLANDULAR MUCOSA - *Adenocarcinomas* are the most common gastric tumor in dogs (but they are still uncommon). The neoplastic cells infiltrate the stomach wall and invade lymphatics. In addition they may spread by transplanted in the abdominal cavity. Carcinomatosis.

SQUAMOUS MUCOSA - The pars esophagus is the common site of origin for gastric *squamous cell carcinomas* in the horse. Squamous cell carcinoma of the horse stomach often invades through the gastric wall and implants on the peritoneal surface of the abdomen.

SMOOTH MUSCLE - *Leiomyomas* are probably the most common benign mesenchymal tumor of the stomach. These tumors originate from the smooth muscle below the gastric mucosa. They can be single or multiple and can become quite large and ulcerate. They can be associated with hypercalcemia or hypoglycemia in the dog.

Lymphosarcoma is the most common tumor in the abomasum of cattle. The mucosa frequently has foci of necrosis and ulceration too with resultant gastric hemorrhage (melena).

Gastric displacement and non-infectious gastritis

Gastric dilation and volvulus

This condition happens in large, deep-chested dogs. As the stomach dilates with gas fermentation and fluid buildup,

If the distension is not relieved, the stomach will continue to rotate into a volvulus. As viewed from behind, the stomach rotates around the esophagus in a clockwise direction.

Because veins are obstructed by the twisted and distended stomach, venous return is reduced, cardiac output is reduced and circulatory shock results. In addition, disseminated intravascular

coagulation, acid- base and electrolyte imbalances and endotoxemia may result. Animals are usually in shock.

Gastric rupture

Gastric rupture is not an uncommon cause of death in horses. In most cases of gastric rupture, there is mechanical or a functional obstruction in the proximal small intestine. This could be an obstruction, displacement, or paralytic ileus. Rupture is usually along the **GREATER CURVATURE** near the omental attachment. The horse dies due to shock and peritonitis.

It should be noted however, that a stomach may rupture after the horse dies due to continued fermentation and gas formation after death. Therefore, you must distinguish *antemortem* from *postmortem* rupture?

Abomasal displacement

The displacement usually is ventrally and to the left of the rumen (LDA), but displacements to the right (RDA) can also occur. Abomasal atony and increased gas production are prerequisites for displacement of the organ. Influx of high concentrations of volatile fatty acids from the rumen, and hypocalcemia, may play a part in instigating hypomotility, while evolution of gas in the abomasum is directly related to the amount of concentrate in the ration. The distended abomasum may sometimes rotate in a counterclockwise direction along with the attached omasum and duodenum resulting in **ABOMASAL VOLVULUS**. This is more common with RDA. Because duodenal outflow is then obstructed, chloride is sequestered in the abomasum and metabolic alkalosis may result. If the vascular ischemia is severe, infarction and abomasal rupture may occur.

Foreign bodies

Phytobezoar (Plant Ball)

A phytobezoar is an accumulation of plant material, much like the trichobezoar. These accumulations can also become impacted and cause obstruction.

Trichobezoars (Hair ball) Calves reared on diets low in roughage or calves reared in confinement often "lick" themselves excessively and swallow their hair (similar to a cat). Most of the hair balls are retained in the rumen but some are found in the abomasum and will occasionally cause obstruction. Of course, cats get hairballs too!!! And rabbits. Can cause

obstruction...

Toxic gastritis

Cantharidin Toxicity - Blister beetles are one example of toxic gastritis in horses. The beetles contain cantharidin, a toxin that causes necrosis and hemorrhage to the delicate gastric mucosa. The beetles live within hay and forage and when the horse ingests the hay, the beetle is also ingested. Cantharidin can also cause ulceration and inflammation in the mouth, esophagus, and urethra.

Salicylate Gastritis - Aspirin and other salicylates can be irritating to the gastric mucosa.

Uremic "gastritis"

Uremia may cause gastric ulceration with hemorrhage (hematemesis and/or melena). Mineral gets deposited where urea contacts bicarb, making blood vessels located nearby brittle. They break, bleed, bingo, ulcers.

Infectious gastritis

Bacterial gastritis

Braxy is caused by *Clostridium septicum*. It occurs in sheep and cattle. The pathogenesis is poorly understood but it is associated with cold weather and ingestion of frost covered foods. The disease occurs most often in young animals during the winter months. Gastric lesions include venous thrombosis and hemorrhage with mucosal hemorrhage and/or necrosis.

Mycotic gastritis

In ruminants, mycotic abomasitis occurs as a sporadic problem almost invariably secondary to insults that cause achlorhydria (or focal atrophy), necrosis, or ulceration under conditions where mycotic colonization can occur. The fungi invade the vasculature resulting in thrombosis and infarction. Mycotic gastritis can also occur in dogs and horses. Affected animals are often presented with a history of long term antibiotic therapy or immunosuppression.

Parasitic gastritis

In ostertagiasis, larval infestation of the mucosa results in gastric gland atrophy. Severely affected animals develop a roughened "Moroccan leather" appearance to the abomasum and

achlorhydria due to the parietal cell atrophy. Animals cannot digest protein, so they get really skinny.

Haemonchus kills a lot of sheep and goats. In severely affected animals large numbers of the characteristic parasites may be present on the abomasal mucosa. This is a disease of blood loss and not a true “gastritis/abomasitis.”

Trichostrongylus axei infection of the equine stomach can result in chronic gastritis. The stomach can have multiple nodules and focal hyperplasia due to *T. axei*.

Gasterophilus intestinalis (bots) infestation in horses results in squamous cell hyperplasia. The "bot" is the larva of the *Gasterophilus* fly and forms a deep attachment in the non-glandular mucosa of the pars esophagus. There is marked hyperplasia of the stratified squamous epithelium adjacent to the *Gasterophilus* sp. larva. Fun to look at, but they don't result in any clinical illness.

Mechanisms of diarrhea

Most diarrheas are due to one or a combination of three basic pathogenic mechanisms:

-malabsorption

-secretion

-effusion

Malabsorptive diarrhea

Decreased absorption of solutes from the lumen occurs in villus atrophy, just because there is not enough surface area to do the required work. The osmotically, (, *Ostertagia* in cattle), the big old osmotic proteins just stay in the lumen all the way through, and drag water with them.

A condition commonly encountered in the intestine is *villus atrophy*. This means that the villi are shorter (and sometimes wider) than they should be. The net result is decreased absorptive area and diarrhea.

Damage to proliferative vs. absorptive compartments

Also known as the crypt, the proliferative compartment is very sensitive to any insult that targets mitotically active cells. What damages mitotically active cells

Viral causes include parvoviruses and bovine virus diarrhea virus.

✓ Radiation injury and mitotic poisons also are very damaging to crypt epithelium.

When damaged, the crypts dilate and the crypt lumens are filled with necrotic debris from the

injured cells. Because the crypts are the source of the enterocytes that cover the villi, the villi are shorter. Therefore, **VILLUS ATROPHY**.

Some agents specifically attack the villus tips, or absorptive areas. When the surface epithelial cells are lost, the villi will contract due to loss, causing the villi to become shorter, therefore **VILLUS ATROPHY**. To distinguish this type of villus atrophy from the previous type, it would be necessary to examine the crypts carefully for signs of damage.

✓ Coronaviruses and rotaviruses both have a predilection for the more mature cells at the villus tip.

✓ Infection with coccidia also tends to cause this type of surface necrosis.

The net result is poor absorption and fluid loss. The fluid loss and resultant electrolyte alterations are the usual cause of death. Besides the lesions seen in the intestine, signs of dehydration throughout the carcass will be evident. How can you tell postmortem if an animal is dehydrated The colonic crypts are damaged by the same insults that attack cells in the crypts of the small bowel. This would include toxins, parvoviruses, and radiation. However, since fewer cells are in mitotic division at any given time, the lesions are less severe than those caused by the same agent in the small intestine.

Secretory diarrhea

Some really bad bacteria, like *E. coli* (certain strains) and *Vibrio cholera*, actually cause the enterocyte to screw up massively. Toxin-mediated increases in cAMP or changes in cGMP shut down sodium chloride cotransport at the luminal cell membrane, reducing passive water absorption. Meanwhile, in crypt epithelium, cAMP-stimulated chloride secretion is promoted and water follows. Thus, the secretory diarrhea is due to toxin mediated increased secretion from the crypts. Other causes of secretory diarrhea are histamine, overproduction of certain cytokines, and some prostaglandins.

Effusive diarrhea

What causes this? Bad damage that wrecks the tight junctions or makes ulcers. If there are holes in the intestine, then body fluid gets sucked into the intestinal lumen and goes out the anus.

COMMON INTESTINAL DISEASES

Terms for inflammation of the intestines: Small intestine - enteritis

Large intestine - colitis

Small and large intestine - enterocolitis Cecum – typhlitis

Rectum - proctitis

Viral diseases of the intestines

PARVOVIRUSES

Canine and feline parvoviruses prefer actively dividing cells (cells with frequent mitosis - hey, that would be the crypt cells!) and thus the severity of the enteritis depends on the turnover rate of the crypt epithelial cells. Because turnover is higher in very young animals, this makes them most susceptible to disease.

Which is why parvo kills so many puppies and kittens.

In parvoviral enteritis, the proliferative compartment is severely damaged. This is the compartment responsible for generation of cells for the villus. Since the virus kills these cells, the villus lacks replacement cells and undergoes atrophy. The villi are shorter and the tips are covered with immature cells resulting in malabsorption in the early stage of the disease. As the disease progresses **erosion** and **ulceration** develops and effusion follows as well as absorption of toxins from the intestines. End result - very sick and big time dehydration.

Any other tissue with rapidly dividing cells may be infected. Most animals have bone marrow hypocellularity, thymic atrophy and some develop myocarditis secondary to the myocardial necrosis. This myocardial necrosis is seen **ONLY** in very young puppies, where there are still some dividing cells in the developing myocardium.

BOVINE VIRUS DIARRHEA VIRUS

Bovine virus diarrhea (BVDV) is caused by a pestivirus in the family *Flaviviridae*. Cytopathic strains of the virus cause crypt cell necrosis and in large and small intestines, sometimes epithelial ulcers in the mouth, esophagus and forestomachs. This syndrome is called "mucosal disease". The pathogenesis is very complicated. Briefly, noncytopathic strains of BVDV are endemic in cattle populations. If a fetus is infected in-utero, it becomes tolerant to the noncytopathic strain and persistently infected. If this animal is later super-infected with a cytopathic strain or the noncytopathic strain mutates to a cytopathic strain, the animal is incapable of mounting an appropriate immune response because of tolerance and the virus causes severe disease.

RINDERPEST

Rinderpest is caused by a Morbillivirus (family *Paramyxoviridae*). This virus causes bloody diarrhea and rapid dehydration. The virus infects both crypt and surface epithelium causing severe erosions.

CORONAVIRUSES

Coronaviruses cause diarrhea in neonatal animals, especially calves. Coronavirus infects both large and small intestines in calves and is responsible for enterocolitis in older calves. The maturation cycle from crypt cell to surface epithelium is slower in neonates. Therefore, neonates develop malabsorptive diarrhea while older pigs may vomit but do not develop severe diarrhea.

ROTAVIRUSES

Species specific rotaviruses occur in most species of mammals and cause neonatal diarrhea. The mechanism is the same as for coronaviruses and is characterized by villus atrophy and malabsorption. The most important diseases are in neonatal calves. Adults are not affected.

Bacterial diseases of the intestines

PATHOGENIC *E. COLI* - Most *E. coli* are not pathogenic; however, several pathogenic strains of *E. coli*

can cause intestinal disease by several different mechanisms.

Enterotoxigenic *E. coli* (ETEC)

Enterotoxigenic bacteria attach to the epithelium using receptor specific pili (singular is pilus). Then, the bacteria release a toxin that disrupts the functions of G proteins that control enterocyte levels of cAMP and cGMP. This stimulates secretion of chloride ion by enterocytes and water and sodium follow passively. This secretion of fluid causes dehydration. Their pilus antigens, K88, K99, and F41, identify these enterotoxigenic strains of *E. coli*. *Vibrio cholerae* (the agent of human cholera) is enterotoxigenic (possesses cholera toxin) and causes secretory diarrhea in humans by a very similar mechanism. ETEC infection is the most common form of neonatal diarrhea caused by *E. coli* in calves, kids, and lambs.

Enterohemorrhagic *E. coli*

Some *E. coli* strains have a shiga-like toxin that kills enterocytes AND causes vascular thrombosis resulting in hemorrhagic diarrhea and systemic disease. The strains are carried by

animals but animals don't get sick from them. But when carrier animals' feces gets into food for humans, LOOK OUT. Cow poops on lettuce, people die. You've seen the headlines.

SALMONELLOSIS

Salmonella spp. are invasive, that is, they are ENTEROINVASIVE. They actually get into the cells. They may enter through M cells, those cells over the Peyer's patches that have many Microfolds. The M cells form a semipermeable sampling barrier above the lymphoid follicle, and they are constantly sampling antigens in the gut.

Salmonella-infected enterocytes suffer. *Salmonella* is a bad guy and makes toxins that cause degeneration and necrosis of enterocytes. As a result there are erosions or ulcers with effusive diarrhea that may include fibrin. In addition, there is often severe vasculitis and thrombosis of mucosal blood vessels. The vascular lesions may be due to action of large amounts of endotoxins absorbed through the damaged mucosa or released locally. This thrombosis further complicates the intestinal lesion, and can result in ischemic necrosis on top of the bacterial-induced necrosis. Wow, we have everything here – necrosis, thrombosis, diarrhea, and megacytokines, so animals are sick sick sick. Lesions are most prominent in the ileum and colon.

Some animals are carriers of *Salmonella* spp. Bacteria may remain indefinitely in the gut-associated lymphoid tissue and mesenteric lymph nodes. The bacteria may be shed periodically and cause disease or a permanent carrier state with intermittent shedding may develop.

The gall bladder is a site of continued infection in some. The famous Typhoid Mary (Mary Mallon), an Irish-born cook in New York City at the turn of the century, was a Salmonella carrier and spread salmonellosis to about 50 people. Salmonellosis in people at that time was due to Salmonella typhi, and the disease is referred to as "typhoid." In Typhoid Mary's day, public health was in its infancy. Government officials decided that the only way they could stop Mary from spreading more salmonellosis was to incarcerate her and so she spent the last half of her life in jail.

CLOSTRIDIUM

There are five types of *Clostridium perfringens*, designated A-E, that are differentiated on the basis of their production of four major antigenic types of lethal exotoxins.

C. perfringens **Type C** is a cause of hemorrhagic enteritis that occurs in all ruminants. It is also seen in foals. Grossly, the intestines are dark red to black and fluid-filled. Mortality is very high. This disease is often referred to as enterotoxemia.

C. perfringens **type D** is a common cause of enterotoxemia in sheep that results in central nervous system lesions.

Clostridial enteritis is usually an opportunistic infection that occurs secondary to imbalances in the normal microflora of the intestine, like when they suddenly get lots of high-energy food to eat. Then the Clostridia in the gut say “yippee” and outgrow their normal flora counterparts. That is not good.

JOHNE’S DISEASE

Johne’s disease, also known as paratuberculosis, is a very large problem for the dairy industry. Caused by *Mycobacterium avium* subsp. *paratuberculosis*, this organism gets into the cow early in life (within the first year), is quiescent for quite a while, and then emerges sometime in adulthood to cause granulomatous enteritis. The lamina propria fills with epithelioid macrophages. There are so many that absorption is impaired, and there is chronic diarrhea. Johne’s disease also occurs in sheep and goats.

To diagnose the disease, an acid-fast stain of the intestine reveals that all of those epithelioid macrophages are filled with *M. avium* subsp. *paratuberculosis* organisms. Organisms are shed in the feces where calves in the herd can pick them up easily.

Animals suffer from a long-term clinical disease characterized by chronic diarrhea and ill thrift. Exacerbation of clinical disease often is associated with parturition, a low nutritional plane, heavy milk yield, and concurrent disease. Emaciation is progressive and ultimately fatal. But the animals continue to appear bright and eat well. Other than the non-stop diarrhea, they are not particular sick.

INTESTINAL PARASITISM

HOOKWORMS

Hookworms (*Ancylostoma* and *Uncinaria*) are a major cause of hemorrhagic enteritis in many species, but especially in dogs and cats. These worms are “vampires”, and attach to the intestinal mucosa to suck blood from the host. Hemorrhage continues when they move to

another location. The result depends on the number of parasites present. With large numbers, an obvious result will be marked loss of blood into the intestinal tract. They are anemia AND hypoproteinemic. That is not good, especially for younger animals.

WHIPWORMS

Whipworms are members of the *Trichuris spp.*, they are species- specific and they cause problems in dogs, pigs, and occasionally cattle. Heavy infection is associated with hemorrhagic typhlitis. The whipworm embeds its anterior end in the mucosa and partially tunnels within the surface epithelium, but does not normally breach the basal lamina. There is blood loss from the worms, loss of absorptive function since the epithelium is damaged, and probably also some loss of protein into the lumen.

NON-INFECTIOUS DIARRHEAS

PROTEIN LOSING ENTEROPATHY

Protein losing enteropathy is a syndrome where protein loss through the intestine is the major abnormality. Diarrhea may or may not be prominent but is usually chronic. *Lymphangiectasia* is one of the more common causes of protein losing enteropathy in the dog. It is associated with a syndrome variably characterized by chronic diarrhea, wasting, hypoproteinemia, lymphopenia, hypocalcemia, and hypocholesterolemia. The lacteals are dilated in the intestinal mucosa and lymphatics are dilated in the serosa and mesentery. These dilated lacteals can be seen grossly as papillate foci in a thickened, transversely folded edematous mucosa. Histologically, the lacteals (which are the lymphatics running down the center of the villus) are very open and way too prominent.

How could this occur? Most cases are due to lymphatic obstruction upstream. What might do this? Lymphosarcoma or granulomatous inflammation in the draining nodes, which are the mesenteric nodes, is probably the most common cause. BUT some cases fall into the so-called idiopathic category. You know, idiopathic just means that we have not yet figured out what the cause is.

The disease is characterized by moderate malabsorption of lipid and there is plasma protein loss into the intestine. This protein loss into the intestine may be the result of increased proprial hydrostatic pressure (or an EFFUSION problem). Hypocalcemia may be related to loss of the mineral bound to plasma protein. Hypocholesterolemia occurs because of

malabsorption of lipid. Animals are lymphopenic because they are losing all that cell-rich lymph into the intestine.

INFLAMMATORY BOWEL DISEASE

Inflammatory bowel disease is a condition of dogs and cats in which the lamina propria contains abnormal cellular infiltrates. The cells may be lymphocytes and plasma cells or they may be eosinophils, giant cells or macrophages. In any case, there is a markedly thickened lamina propria. It usually affects the small intestine, and used to be known as lymphoplasmacytic enteritis.

The net effect of infiltration in the lamina propria is that absorption is impaired because there are too many cells in the way and cytokines from the inflammatory cells may interfere with normal enterocyte function. Tight junctions may become leaky due to exocytosis of cells. Consequently nutrients are lost due to the malabsorption and effusion.

The cause is unknown - in cats, some may be due to dietary antigens.

ULCERATIVE COLITIS DUE TO NSAIDS

Because of their anti-prostaglandin activity, non-steroidal anti-inflammatory drug therapy can cause ulcers in the stomach, small intestine, and colon. The **right dorsal colon is a particularly sensitive area in the horse** and large areas of ulceration resulting in effusive loss of plasma and fluids follows. It probably occurs as a result of vascular compromise.

CYATHOSTOMES

Cyathostomes, or small strongyles, cause lesions as the larval stages migrate into the deep mucosa of the cecum and ventral colon of the horse. These larvae persist there, and often emerge as a big group in the spring. Horses have diarrhea at the time of this group emergence.

INTESTINAL COCCIDIOSIS

Coccidiosis is a common cause of hemorrhagic typhlocolitis in cattle. Caused by *Eimeria bovis* in cattle, it is typically a disease of intensively managed animals and tends to be most severe in winter, when animals are stabled together and so exposed to higher levels of oocysts shed in feces. Sporozoites infect intestinal epithelial cells and undergo schizogony. The schizont fills the host cell, eventually rupturing (and it ruptures the host cell along with it) to release merozoites which then infect other epithelial cells. At some point, some of the merozoites develop into macrogametes and microgametocytes, the sexual stages that produce

oocysts. Oocysts are then shed to infect others. There is malabsorption due to mucosal damage in the cecum and colon. There may be bright red blood in the feces, since the hemorrhage is so close to the back door and doesn't have much time to oxidize prior to exit.

Coccidiosis in species other than cattle is a small intestinal rather than large intestinal problem. Coccidiosis also occurs in sheep (*Eimeria ovina*) and goats (*Eimeria ninakohlyakimovae*) and can be a cause of significant morbidity and mortality. Puppies and kittens get *Isospora canis* and *Isospora felis*, respectively.

Cryptosporidium parvum is a member of the Apicomplexa family of protozoan parasites that is smaller than most other common coccidia. It attaches to the apical surface of enterocytes and **destroys microvilli**. As a result, infected animals (many species can be infected - perhaps cattle are the most frequent victims) have malabsorption, diarrhea, and weight loss.

LIPOMAS

Lipomas that form on the mesentery in the abdominal cavity can become pendulous. On rare occasions the lipoma may swing like a pendulum and entrap segments of intestines.

INTUSSUSCEPTION

Intussusception involves the telescoping of one segment of bowel into an outer sheath formed by another, usually distal segment of intestine. It is usually the proximal portion that telescopes inside the flaccid distal portion. The efferent veins associated with the mesentery on the entrapped portion are compressed and venous outflow is blocked. As a result, the inner portion of the telescoped part swells with edema and congestion. The adjacent apposed serous surfaces may become adherent as fibrin and inflammatory cells effuse from the affected bowel.

Unfortunately, just finding an intussusception at postmortem is not enough to make a diagnosis. These intussusceptions may occur just after death and have no clinical significance. Consequently, to determine if the intussusception is antemortem, it is necessary to find some signs of inflammation associated with it

- redness, edema, fibrin exudation, etc. Intussusceptions cause complete obstruction of the passage of intestinal contents. As with many of the ischemic intestinal syndromes, animals are usually in severe abdominal pain.

ISCHEMIA AND ITS OUTCOME

In all these cases of displacements, there is no dysfunction unless there is entrapment and subsequent compromise of the vascular supply. Ischemic changes are seen first at the villus tips and with time involve more of the wall.

The primary factor in the progression and outcome of ischemic conditions is the *degree* and *duration* of ischemia. Rapid intervention is necessary for successful outcomes. Short-term ischemia with preservation of at least the base of the crypts of Lieberkuhn will permit resolution, as proliferation of cells in the crypts reepithelializes the mucosal surface within 1 to 3 days. Inflammatory cells remain until the surface is completely covered and by 2 weeks the healing is usually complete.

Persistent ischemia results in necrosis involving all mural layers. The full thickness of the intestine wall ultimately becomes gangrenous, green-brown or black, flaccid, and friable. The only effective solution for transmural necrosis is removal and resection.

A common sequela to intestinal ischemia is absorption of endotoxins through the devitalized intestines. The bacteria in the gut (and there are a lot of these) suddenly have access to exposed blood vessels and take the opportunity to ride around the body. This is bad nooz, also called sepsis.

INTESTINAL OBSTRUCTION

Intestinal obstruction is not immediately life threatening but can become so if not corrected. Obstructions in the upper intestine cause vomiting or gastric reflux whereas more posterior obstructions may not. There may be intense pain. Common forms of obstruction include **foreign bodies** that may perforate, impactions of dry feed, and a functional disturbance called "**ileus**" (also called "paralytic ileus"). Ileus is failed peristalsis. It can occur secondary to various types of intestinal disturbances, obstructions, peritoneal irritations, and following abdominal surgery.

VASCULAR THROMBOSIS

Vascular thrombosis used to be a major cause of colic in horses, but is seen less frequently due to the widespread usage of effective anthelmintics. It resulted from thromboembolism from

thrombi in the anterior mesenteric arteries where larvae of *Strongylus vulgaris* had migrated as part of their normal life cycle. The syndrome is referred to as thromboembolic colic.

Intestinal anomalies

ATRESIA AND STENOSIS

A complete segmental obstruction of the lumen of the digestive tract is called *atresia*. This is usually due to occlusion of a segment by a membrane or failure of a segment to form an open lumen. The two blind segments may be joined by a cord of connective tissue. *Stenosis* implies a segmental narrowing without complete occlusion of the lumen.

Atresia ani (imperforate anus) is sometimes seen in newborn farm animals. Meconium is retained and colonic distention occurs. The animals rarely survive more than a few days. *Atresia coli* is the most common segmental anomaly in domestic animals and involves the colon.

LETHAL WHITE FOAL SYNDROME

White foals born from Overo paint parents may have an abnormal condition called colonic agangliosis. There is a congenital absence of nerve ganglia in the colon. Both cutaneous melanoblasts and myenteric nerve cells are derived from neural crest cells. In these foals, there is a defect in migration of these neural crest cells resulting in agangliosis and white hair and skin color. Lack of nerve supply to the colon results in segmental stenosis and probably lack of proper peristalsis. The foals die a few days after birth with severe colic.

MEGACOLON

Megacolon is a common sequela to colonic or rectal obstruction. The colon becomes markedly distended and flaccid. Obstruction may be due to a neoplastic mass in the pelvic canal, rectal stricture, obturation from a luminal mass, fractured pelvis, abscess or adhesions. Manx cats develop megacolon due to a neurological deficit secondary to vertebral and spinal cord anomalies.

Intestinal Neoplasia

What is true of all organs is the same for the intestine - that is, tumors usually arise from the resident cell population there.

There are four types of *mesenchymal* tumors seen in the intestine.

Lymphosarcoma is the most common type of mesenchymal intestinal tumor in animals. It is most prevalent in the cat. These may be primary in origin but more commonly, the intestinal tumor is part of multicentric lymphosarcoma. Grossly the tumors are fleshy, white, and homogeneous. What would be some other mesenchymal tumors in the intestine? Do you remember what smooth muscle tumors are called? *Leiomyoma and leiomyosarcoma*. These tend to be nodular rather than diffuse and they ulcerate and cavitate on the luminal surface. They are found most often in the small intestine.

Epithelial tumors can certainly occur in intestinal tissue. Since epithelium in the intestine is glandular in origin, they are referred to as *adenomas* and *adenocarcinomas*. They are relatively uncommon in animals. One characteristic of adenocarcinomas in the intestine is that they tend to erode through the intestine wall and “seed” the peritoneal mesentery, so that neoplastic nodules. One big problem with adenocarcinomas is that they often form constrictions causing partial or total obstruction of the lumen. The section of intestine proximal to the obstruction will be very dilated.

Intestinal displacements and vascular injury

HERNIAS

Umbilical hernias are a common lesion in some domestic animals, notably foals and calves. The defect is due to abnormal enlargement of the umbilical “ring” of skin and peritoneum and NOT due to any abnormality in the small intestines. These hernias are detected at birth and generally cause no problems UNLESS intestines get into the herniated sac and can't get back out. In this case, when they become entrapped and ischemic, it is life threatening.

Inguinal hernias are similar to umbilical hernias except that in inguinal hernias, the abdominal viscera hangs out the inguinal ring. Sometimes intestines can herniate all the way

into the scrotal sac and in this case they are called scrotal hernias. Trauma is a predisposing factor for intestines entering the inguinal ring although the hernias may occur without any obvious predisposing factor.

In a *diaphragmatic hernia*, abdominal contents move through a hole in the diaphragm to reside in the thorax. These diaphragmatic holes may be congenital or, more commonly, are due to trauma, especially as when animals are hit by cars. Sometimes the herniated viscera don't cause any problems but more commonly respiratory signs are seen as too many things in the thorax compress the lungs.

All of the above are examples of abdominal contents herniating outside the abdominal cavity. In fact, *internal hernias* can occur as well, such as when one part of intestine herniates through a narrow opening within the abdominal cavity.

One usual site for herniation to occur is the epiploic foramen. The small intestine can become incarcerated in the area of the liver and stomach if it herniates through the epiploic foramen and cannot return. Another site for internal herniation is the nephrosplenic space formed by the dorsal end of the spleen, its renal ligament, the left kidney, and the ventral spinal muscles.

TORSION AND VOLVULUS

These two words inevitably cause a great deal of confusion. *A torsion is a twist of the intestine;*

a volvulus is a twist of the mesentery. Most of the twisted intestines that we see in animals are volvulus.

The condition is life threatening as the obstruction of efferent veins causes intestinal ischemia, which, is an emergency. With compression due to twists, the veins are the first to collapse. The arteries, which have greater structural integrity, still function and continue to pump blood in. But, because the veins are effectively obstructed, a tremendous amount of venous blood swells the tissue, causing ischemia. These twisted intestines are dark red to purple to black because of all the venous blood they contain.

Liver - Response to Injury

Hepatic lipidosis is probably the most common response of the liver to injury. Fatty change is a reversible change that occurs when either too much triglyceride is presented to the liver or too little apoprotein is made to transport lipid out of the liver *Centrilobular hepatic necrosis* is

the most frequently observed type of hepatic necrosis. The hepatocytes around the central vein are the most vulnerable to anoxia and nutritional compromise because they are at the end of the line. *Periportal necrosis* is less common and is usually caused by toxin that comes into the liver and interacts with microsomal enzymes found near and around the periportal areas.

Regeneration

The liver is one of the few organs that can regrow itself. Regenerative nodules tend to be very lipid laden and often do not maintain the normal lobular architecture of the liver. Regenerative nodules are often called hyperplastic nodules and the condition is known as nodular hyperplasia.

Fibrosis

There is a delicate lining of fibrous reticular connective tissue that supports the hepatocytes and hepatic vasculature. This framework must be intact for regeneration to occur. If this framework is damaged, then fibrosis will occur instead of regeneration.

Cirrhosis

In some damaged livers, necrosis, regeneration/hyperplasia and fibrosis can be seen occurring concurrently. This combination is called cirrhosis. In chronic cases, nodular regeneration and fibrosis predominate and this is called “end stage liver”. Cirrhotic livers are firm and lumpy-bumpy due to the nodular hyperplasia combined with fibrosis.

INFECTIOUS HEPATITIS

Several infectious agents can cause inflammation of the liver.

VIRUSES:

In dogs, *infectious canine hepatitis* caused by canine adenovirus-1 is characterized by icterus, and enlarged liver. This virus loves endothelial cells and also hepatocytes so although there are multiple organs affected by hemorrhage, the liver gets the worst hit. This disease is very rare in the U.S. because of widespread vaccination - so there just isn't much virus around to infect animals.

Intranuclear inclusions are screaming, “I AM A VIRUS!”

All the *herpesviruses* target the liver but usually only cause lesions (multifocal hepatic necrosis) in the fetus. Think BHV-1, think EHV-1. Pacheco's disease of psittacines, another herpesvirus, will cause multifocal hepatic necrosis in adults.

Look carefully at the liver to see the multiple white dots that mean a virus has been here!

Viral hemorrhagic disease (VHD) of rabbits is also a disease that shows up from time to time. This disease is caused by a calicivirus, in fact some reports refer to it as Rabbit Caliciviral Disease. It is spread by fecal-oral transmission, gets in and kills the rabbits very quickly. They die in 2 or 3 days with massive liver failure because the virus loves hepatocytes so much and just reproduces there really really fast. Rabbits often die with DIC because the liver is gone and all the clotting factors are totally out of whack. (The liver is where all the clotting factors are made.)

CLOSTRIDIA:

Clostridium piliforme (formerly known as *Bacillus piliformis*) is an intracellular bacterium, which causes focal necrotizing hepatitis in rodents, foals, dogs and cats. The disease is known as Tyzzer's disease. *Clostridium piliforme* has been known for a long time as a cause of severe losses in laboratory rodents. Although the disease is probably initiated by an intestinal infection, lesions in the gut are less specific and constant than those in the liver, which consist of focal hepatitis and necrosis. Affected foals usually die between the ages of 1 to 4 weeks.

Clostridium novyi causes a disease in sheep called black disease or necrotic hepatitis - This organism is found in soils and grazing animals are constantly ingesting it. Some cross the mucous membranes and get taken up by phagocytes, remaining latent in Kupffer cells in the liver. Then, when something happens to the liver to cause an anaerobic focus, they go wild and replicate, spewing their nasty toxins. The livers are ROTTEN and the skin has some characteristic and severe venous congestion, which is how the disease got its name. The most common inciting cause is FLUKES that get in and migrate to create anaerobic focus.

Clostridium haemolyticum causes a disease in both cattle and sheep called **bacillary hemoglobinuria**.

The pathogenesis is very much like *Clostridium novyi* except that the toxins cause predominantly intravascular hemolysis, so that there is massive destruction of red cells with resulting hemoglobinuric nephrosis and the urine is red-brown.

OTHER BACTERIA:

Hepatic **necrobacillosis** occurs after an assault on the rumen, such as might occur with grain overload, and ruminal organisms get in and “seed” the liver. The result is multiple areas of necrosis which then become abscesses.

This is usually seen in feedlot steers. *Fusobacterium necrophorum* starts it, then other bacteria join the party.

Leptospirosis is caused by a number of organisms and most serovars prefer certain species. The leptospira will grow in hepatocytes and kidney so both of these organ systems are affected. There will be generalized icterus. Leptospira are shed in urine and so disease tends to happen during very wet periods, as urine contaminates standing water and then the organisms are very available to other animals splashing through it.

TOXIC HEPATITIS

The liver gets more toxic injury than any other organ. This is because it directly receives all the portal blood (which comes from the intestine) and so is exposed to all ingested substances. Consequently any toxin which is ingested will hit the liver first. Also, the liver contains an enzyme system, cytochrome P- 450, a major enzyme organization involved in drug metabolism. As drugs or other ingested substances get metabolized, even if they weren't toxic to begin with, sometimes the metabolites that are created by the liver enzymes, turn out to be toxic and kill the liver cells.

Drug-Induced Liver Disease

✧ Mebendazole occasionally can produce acute diffuse hepatic necrosis, and oxybendazole-diethylcarbamazine has been associated with nonspecific hepatitis in dogs.

✧ Anticonvulsants such as primidone, phenytoin and phenobarbital produce chronic hepatic disease after long-term use, which may progress to cirrhosis and hepatic failure after 2-3 years.

✧ Thiacetarsamide has been used to treat dogs for heartworm disease and can produce acute hepatic injury and liver failure.

In cats, acetaminophen toxicosis produces severe oxidative stress to hepatocytes as cats lack the ability to conjugate glucuronides for detoxification of the drug.

✧ Overzealous administration of corticosteroids (or endogenous overproduction) will result in glycogen accumulation in hepatocytes, which appear as a fine vacuolation. This is called *steroid hepatopathy*.

Hepatotoxins in Nature and Feed

Pyrrolizidine Alkaloids

This is a common cause of liver disease in certain regions, especially in the southeastern United States (like Georgia). It is caused by a variety of toxic plants which contain pyrrolizidine alkaloids that cause hepatic necrosis and fibrosis with bile duct hyperplasia.

Plants that contain pyrrolizidine alkaloids include: *Amsinckia* spp. (e.g. fiddleneck), *Crotalaria* spp. (e.g., Rattlebox), *Cynoglossum* spp. (e.g., hound's tongue), *Echium* spp. (e.g., Salvation Jane), *Heliotropium* spp. (e.g., common heliotrope), and *Senecio* spp. (e.g., ragwort, groundsel, and tar weed). Obviously this is a problem for grazing animals only.

☐☐Aflatoxins

Corn can be contaminated with *Aspergillus flavus*, a mold that produces *aflatoxin* as a metabolite. Aflatoxins ingested by animals may be further metabolized by the hepatic mixed function oxidation system with resultant hepatic toxicity. Other toxic effects include carcinogenesis, teratogenesis, and immunosuppression.

Cyanobacteria (blue-green algae) -

When fertilizer-heavy runoff (with plenty of nitrates and phosphates) gets into ponds, these cyanobacteria organisms may proliferate. Animals drinking the water may succumb quickly to liver failure. Ruminants are preferentially affected, but it can be seen in horses, sheep, and dogs as well. The toxins get into hepatocytes and inhibit protein synthesis and disrupt the cytoskeleton so that cells die rapidly. There will be massive hepatic necrosis with hemorrhage.

Amanita mushrooms

The amanitoxins inhibit protein synthesis in the liver which causes death. Grossly livers have massive necrosis and there may be extensive hemorrhaging in the carcass as well. This is seen most commonly in dogs

What is the day job of the hepatocytes? Many tasks! They make all the serum proteins. They process all the carbohydrates, lipids and amino acids from the gut, which also means they get first exposure to anything BAD that is in the gut, like ingested toxins. They have specific detoxifying mechanisms in their cytoplasm so that blood-borne, non-body compounds get metabolized here (for instance, medicines!).

Chronic Active Hepatitis

Chronic active hepatitis is a progressive inflammatory condition associated with a variety of predisposing causes, including canine hepatitis, leptospirosis and copper toxicosis, plus others. The condition progresses to liver failure. Liver looks (is) cirrhotic.

Copper Toxicosis –

a problem in Bedlington terriers and sheep (they kind of loolike, don't they?) Copper toxicosis is a metabolic disorder in dogs in which hepatic accumulation of dietary copper produces progressive .

hepatopathy with cirrhosis and liver failure. Breeds most often affected include a number of terriers, especially Bedlingtons, where it has a genetic basis.

In sheep, copper toxicity is usually a chronic problem with an acute crisis. Excessive copper accumulation occurs either through too much intake or deficiency of molybdenum in the diet. The copper accumulates in the lysosomes of the hepatocytes. The normal cellular turnover ensures that as the copper comes out of the turned-over hepatocytes it gets taken up by new hepatocytes. But if the turnover in the liver gets excessive, such as might happen with starvation, then there is too much copper in the blood stream and there is intravascular hemolysis of red cells, and liver failure. Kidneys are a characteristic very dark color.

Hepatic Lipidosis

A severe accumulation of fat in the liver, termed hepatic lipidosis, occurs especially in cats and horses. The pathogenesis of this condition is poorly understood. Affected cats have an enlarged fatty liver and are hyperlipemic. The condition is often associated with a recent stress event. It may be secondary to diabetes mellitus, malnutrition or exposure to drugs or toxins. Obese ponies and horses in negative energy balance are susceptible to developing equine hyperlipemia. In these animals, there is thought to be increased mobilization of fat from body stores along with decreased protein intake.

Neoplasia

Various neoplasms can involve the liver. Primary neoplasms are of hepatocytes and are called hepatomas or hepatocellular carcinomas. There really isn't a benign form, so the two terms are synonymous and also bad nooz.

Metastatic liver neoplasia can arise from several organs. Probably the most common are mammary gland adenocarcinoma, or hemangiosarcoma or pancreatic carcinoma in dogs.

Note: Both lung and liver are the two organs that are more commonly affected by metastatic tumors than by primary tumors.

THE BILIARY SYSTEM

GALLBLADDER DISTENTION

Gall bladder distention is a common finding at postmortem in animals that are anorexic. Remember, gall bladder emptying is “triggered” by food going by the bile duct opening in the small intestine. If the animal is not eating, there is no stimulus for bile excretion.

CHOLELITHS

Choleliths, also known as gallstones, are rare in animals. The condition is called *cholelithiasis*.

VOCABULARY FOR BILIARY SYSTEM INFLAMMATION

- □ Inflammation of the gall bladder is termed *cholecystitis*.
- □ Inflammation of the bile ducts is *cholangitis*.
- □ The most common form of inflammation involving the biliary tree includes inflammation of the periportal areas of liver. This is called *cholangiohepatitis*.

PARASITIC CHOLANGIOHEPATITIS

Fluke infestation is not uncommon in ruminants. Affected livers are often black. The black pigment in the liver parenchyma and hepatic lymph node is the result of infection with flukes. The flukes regurgitate partially digested blood, which is black, into the liver and some is carried to the lymph nodes by macrophages.

BACTERIAL CHOLANGIOHEPATITIS

Bacterial cholangiohepatitis is usually caused by nonspecific organisms, such as coliforms and other gut microbes that move up into the bile duct from the small intestine.

CHOLESTASIS

Bile stasis is called *cholestasis*. Bilirubin is a breakdown product of old red cells. This process takes place in macrophages after which bilirubin is released into circulation (unconjugated bilirubin) lightly bound to albumin. Hepatocytes process bilirubin, conjugate it with glucuronic acid and excrete it as bile.

ICTERUS

Icterus, also known as *jaundice*, is a yellow discoloration of tissues and body fluids by an excess of bile pigments. It is traditionally regarded as having two basic causes –

1) overproduction of bilirubin (as in the case of hemolytic disease). This is PRE-HEPATIC jaundice.

2) impaired excretion of bile from the liver.

The latter, cholestasis, may be conveniently subdivided into –

1) failure of uptake or conjugation of un-conjugated bilirubin (primary liver disease) - HEPATIC jaundice

2) inability to excrete conjugated bilirubin (primary biliary disease); the gall bladder is plugged - POST-HEPATIC jaundice

BILE DUCT OBSTRUCTION

Unlike people, biliary obstruction in animals is rarely due to gallstones. In most cases it is due to severe cholangitis with the obstruction being caused by inflammatory cells, sloughed debris, or a compressing tumor.

BILE DUCT NEOPLAS

Cholangiocellular adenomas (bile duct adenomas) are benign neoplasms of the bile duct epithelium. Affected animals may present with icterus if the neoplasm obstructs the common bile duct.

Cholangiocellular carcinomas (bile duct carcinomas/adenocarcinomas) are the malignant counterparts. In dogs and cats, the species most often affected, the tumors are usually multifocal suggesting that the inciting cause affected bile ducts in multiple locations. Grossly, these tumors are pale and have an umbilicated (sunken centrally) appearance on the capsular surface.

THE PANCREAS

NORMAL PANCREAS

Pancreas has two functions. The exocrine pancreas makes digestive enzymes such as protease, lipase, and amylase, that are secreted into the intestine via the pancreatic duct. The endocrine pancreas consists of scattered Islets of Langerhans which produce and secrete insulin and glucagon directly into the bloodstream.

Hypoplasia Or Atrophy?

Developmental derangements can result in pancreatic hypoplasia. In these cases, the pancreas is difficult to recognize in the mesentery of the duodenum and the pancreatic tissue is markedly reduced in size.

Atrophy would imply that the organ had at one time been completely developed, and is now reduced in the amount of tissue due to some insult. Without further information however,

atrophy and hypoplasia could be difficult to differentiate. Some dogs are genetically predisposed to exocrine pancreatic insufficiency. Signs usually begin to manifest when dogs are 6-12 months of age. German shepherds are overrepresented. Affected animals are unable to digest food properly due to a lack of pancreatic enzymes, and weight loss occurs. These animals have voracious appetites and excrete large amounts of undigested food in the feces that are high both in fat (steatorrhea) and protein.

Acute Pancreatitis/ Acute Pancreatic Necrosis

Pancreatitis can occur in many species, but is mostly diagnosed in dogs, especially if fed a high fat, low protein diet. The disease can even occur secondarily to surgical manipulation. This disease has been given various names. In addition to “acute pancreatic necrosis”, this condition is also called “acute necrotizing pancreatitis” or “acute hemorrhagic pancreatitis”. The reason for all the different names is the variety of lesions that one can see depending on the stage of the disease at death of the animal. The multitude of names reflects the vicious circle nature of the disorder - necrosis starts inflammation which causes more necrosis, etc. Basically, any time you have lipase out in an area where there are fat cells, bad things are going to happen.

PERIPANCREATIC FAT NECROSIS often occurs in pancreatitis. The term "saponification" has been used to describe this lesion in fat, due to the "soap-like" alteration of the triglycerides released from the adipocytes.

Pancreatic Amyloidosis

Amyloid is not a single chemical substance, but an extracellular deposition of a variety of abnormal fibrillar proteins that look alike histologically. Amyloid in the pancreas is also called insular amyloidosis and is thought to be due to overproduction of a protein known as islet amyloid polypeptide by the islet cells themselves. This is a common problem in older cats. Production and accumulation of islet amyloid is almost always associated with varying degrees of diabetes.

Infectious Pancreatitis

Hardly ever occurs. Parasites such as *Strongylus equinus* can cause pancreatitis in horses secondary to aberrant migration.

Pancreatic Neoplasia

With ALL organs, when you think of neoplasia, think of the cell types that live there. In the pancreas, the two main cell types are exocrine glandular cells and endocrine cells.

□ □ If the neoplasm arises from the exocrine or ductular cells, it is termed a pancreatic exocrine adenoma or adenocarcinoma/carcinoma (either of these terms is correct). The malignant forms usually.

metastasize early and to the liver. Sometimes liver problems are noted before any pancreatic problems are detected.

□ If the neoplasm arises from the endocrine cells, specifically the beta cells of the islets, it is termed an insulinoma if benign, or islet cell carcinoma if malignant. Ferrets are often affected by these benign tumors. In other species, the malignant counterpart is seen more frequently and also metastasizes to the regional lymph nodes and liver.

Both benign and malignant islet cell tumors frequently synthesize and secrete insulin and this often results in hypoglycemia.

What is the day job of the hepatocytes? Many tasks! They make all the serum proteins. They process all the carbohydrates, lipids and amino acids from the gut, which also means they get first exposure to anything BAD that is in the gut, like ingested toxins. They have specific detoxifying mechanisms in their cytoplasm so that blood-borne, non-body compounds get metabolized here (for instance, medicines!).

metastasize early and to the liver. Sometimes liver problems are noted before any pancreatic problems are detected.

□ If the neoplasm arises from the endocrine cells, specifically the beta cells of the islets, it is termed an insulinoma if benign, or islet cell carcinoma if malignant. Ferrets are often affected by these benign tumors. In other species, the malignant counterpart is seen more frequently and also metastasizes to the regional lymph nodes and liver.

Both benign and malignant islet cell tumors frequently synthesize and secrete insulin and this often results in hypoglycemia.

What is the day job of the hepatocytes? Many tasks! They make all the serum proteins. They process all the carbohydrates, lipids and amino acids from the gut, which also means they get first exposure to anything BAD that is in the gut, like ingested toxins. They have specific detoxifying mechanisms in their cytoplasm so that blood-borne, non-body compounds get metabolized here (for instance, medicines!).